

Reducing Abdominoplasty Complications

The authors recommend using progressive tension sutures in abdominoplasty procedures. This suture technique not only eliminates dead space but also securely advances the flap with incremental tension transferred from the skin closure incision to the superficial fascial system. (*Aesthetic Surg J* 2002;22:475-476.)

Many articles address the high rate of complications associated with abdominoplasty, with particular concern for the combination of abdominoplasty and lipoplasty. In an abdominoplasty panel discussion featured in *Aesthetic Surgery Journal*, Dr. Toledo¹ stated, "the incidence of seroma is 100 percent when lipoplasty and abdominoplasty are combined." He also recommended separating these procedures by 6 months. To reduce the incidence of complications associated with abdominoplasty, surgeons have advocated prolonging wound suction drainage, using various compression devices, limiting postoperative ambulation, restricting resumption of an upright posture, and limiting or delaying associated lipoplasty.^{1,2}

Our experience, and the experience of other surgeons, is that abdominal lipoplasty and abdominoplasty can be combined without resulting complications of seroma formation or distal flap necrosis by adding progressive tension sutures (PTS).^{2,3} The basic concept is to control redraping and advancement of the abdominal skin flap by placing multiple sutures from the superficial fascia to the deep fascia (Figure 1). It has been our experience that adding PTS when performing abdominoplasty with abdominal lipoplasty results in effective and safe procedures. In the series reported, seromas, hematomas, necrosis, and hypertrophic scars were not observed. Because dead space is minimized, drains are not necessary; however, a compression garment is used. Convalescence is shortened, and early ambulation is possible.

Lipoplasty of the upper abdomen, performed before surgical dissection, is generally limited to the fat deep to Scarpa's fascia. Wide undermining of the lower abdomen and limited undermining of the more lateral areas of the upper abdomen allow for exposure and plication of the diastasis rectus while maintaining more blood supply. Matarasso⁴ refers to this limited upper abdominal dissection as "inverted V."

Progressive tension sutures are then placed from the superficial to the deep fascia as the abdominal flap is advanced (Figure 2). This distal advancement is maintained as each suture is placed and tied (hence, the designation, "progressive tension sutures"). Here, tension is redistributed over a broad area of the abdominal flap as compared with the conventional procedure in which all the tension is concentrated on the incision. Therefore, with the PTS technique, you can close the incision with virtually no tension (Figure 3).

Do not confuse these sutures with Baroudi's⁵ "quilting sutures," which are placed from the subcutaneous fat to the deep fascia. Quilting sutures are intended simply to eliminate dead space and do not provide flap advancement. Because the fat deep to Scarpa's fascia is suctioned, PTSs are actually placed securely from the superficial to the deep fascia, effectively and securely advancing the flap with incremental tension transferred from the skin closure incision to the superficial fascial system (secured to the deep fascia).



Harlan Pollock, MD, Dallas, TX, is a board-certified plastic surgeon and an ASAPS member.



Todd Pollock, MD, Dallas, TX, is a board-certified plastic surgeon and an ASAPS member.

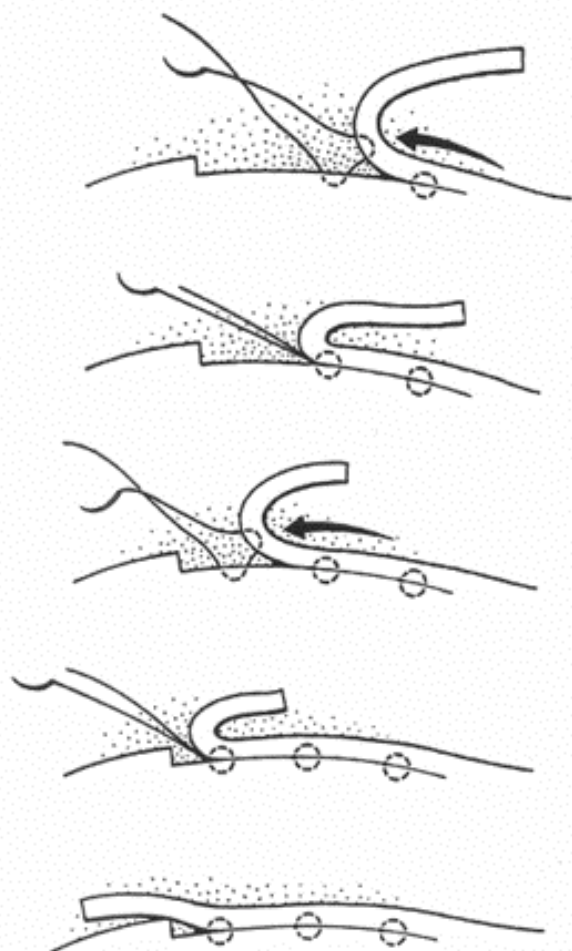


Figure 1. With PTSs, the skin flap is advanced with the placement of each suture and dead space is reduced.

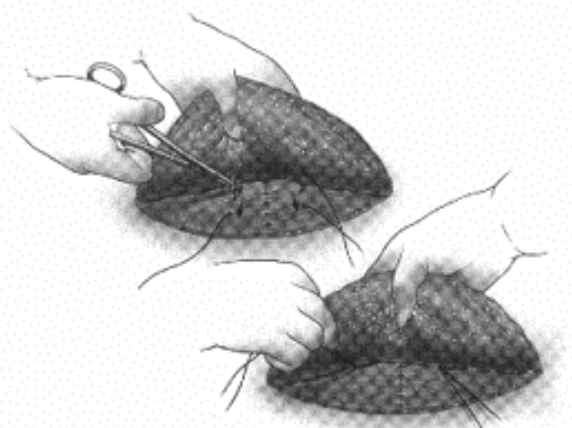


Figure 2. The placement of PTSs.

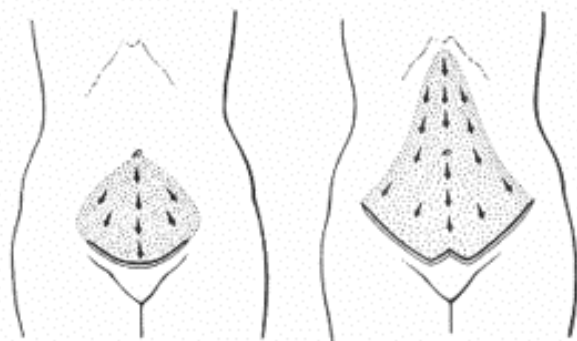


Figure 3. The distribution of PTSs.

Conventional wisdom has been to use caution when combining lipoplasty with abdominoplasty, and some surgeons advocate avoiding lipoplasty completely when performing abdominoplasty. However, our experience suggests that causative factors in high complication rates associated with this combination of procedures may be unrelated to the addition of lipoplasty. Other risk factors must be considered, such as dead space created by extensive undermining,⁶ excessive tension on the skin flap closure, or the shearing or separation effect on healing tissue planes related to patient movements.⁷ In our experience, using PTSs addresses most of these risk factors, lowers the incidence of local complications, and shortens convalescence. ■

REFERENCES

1. Armand L, Hunstad J, Saltz R, Toledo L. Panel discussion: issues in abdominoplasty. *Aesthetic Surg J* 2000;20:403-409.
2. Pollock H, Pollock T. Progressive tension sutures: a technique to reduce local complications in abdominoplasty. *Plast Reconstr Surg* 2000;105:2583-2586.
3. Mladick R. Progressive tension sutures to reduce complications in abdominoplasty. *Plast Reconstr Surg* 2001;107:619.
4. Matarasso A. Liposuction as an adjunct to full abdominoplasty revisited. *Plast Reconstr Surg* 1995;95:829-836.
5. Baroudi R, Ferreira C. Seroma: how to avoid it and how to treat it. *Aesthetic Surg J* 1998;18:439-441.
6. Matarasso A. Discussion: abdominal dermolipectomies: early postoperative complications and long-term unfavorable results. *Plast Reconstr Surg* 2000;106:1619.
7. Baroudi R. Discussion: liposuction as an adjunct to full abdominoplasty revisited. *Plast Reconstr Surg* 2000;106:1203.

Reprint requests: Todd Pollock, MD, 8305 Walnut Hill Ln., Suite 210, Dallas, TX 75231.

Copyright © 2002 by the American Society for Aesthetic Plastic Surgery, Inc.

1090-820X/2002/\$35.00 + 0 70/1/128621

doi:10.1007/maj.2002.128621